



# Determining the accuracy of measurement of alveolar bone crest level and bone plate thickness with cone-beam computed tomography using different voxel size

Shruthi S. Fasalkar, G. Shubha, B. N. Praveen, A. R. Shubhasini, G. Keerthi, Nirza Mukhia

Department of Oral Medicine and Radiology, KLE Society's Institute of Dental Sciences, Bengaluru, Karnataka, India

## Keywords:

Alveolar bone, cone-beam computed tomography, cortical bone

## Correspondence:

Dr. B. N. Praveen, Department of Oral Medicine and Radiology, KLE Society's Institute of Dental Sciences, Bengaluru, Karnataka, India. Mobile: +91-9845136960. E-mail: praveen.birur@gmail.com

Received: 10 November 2019;

Accepted: 18 December 2019

Doi: 10.15713/ins.jmrps.164

## Abstract

**Background and Objectives:** Cone-beam computed tomography (CBCT) offers isotropic voxels of various sizes. The smaller the voxel size, the greater the spatial resolution, rendering better precision for measurement. On contrary, smaller the voxel size, greater is the amount of radiation. Literature offers few studies on image acquisition protocol measuring thin structures such as buccal and lingual bone plate. Thus, this study was conducted to evaluate the accuracy of the measurement of bone crest level, buccal and lingual bone plate thickness in images obtained with voxel sizes 0.2 mm and 0.4 mm. **Materials and Methods:** Fifteen partially dentulous mandibles with three posterior consecutive teeth were taken for the measurement of alveolar crestal bone height. Fifteen edentulous sites with posterior sockets were taken for measuring buccal and lingual bone plate thickness, which were scanned by CBCT using 0.2 mm and 0.4 mm voxel size. Direct measurements were done using digital Vernier caliper.

**Results:** There was no statistical significance on comparison between 0.2 mm voxel and 0.4 mm with direct measurement for alveolar bone thickness and crestal bone height. On comparison between 0.2 mm and 0.4 mm voxel measurements, there was a statistical significance.

**Conclusion:** The study concluded that 0.2 mm voxel was precise and had a good accuracy in measuring small anatomical structures.

## Introduction

Imaging is a significant diagnostic aid in diagnosis, treatment plan, and prognosis. Introduction of cone-beam computed tomography (CBCT) in imaging maxillofacial region leads to true shift from two-dimensional (2D) to three-dimensional to overcome intrinsic limitation of 2D projection such as magnification, distortion, superimposition, and misinterpretation of structures.<sup>[1]</sup> CBCT provides a complete view of maxillae, mandible, teeth, and supporting structures with high spatial resolution and lower radiation dose to the patient.<sup>[2]</sup> The most common indication of CBCT in dentistry are to visualization of periodontal structures, carious lesions, temporomandibular joints, airways, and pathology of head and neck.<sup>[3]</sup> It also helps to measure the alveolar bone for orthodontic treatment for the placements of peri-implant for anchorage and periodontal treatment for the placement of grafts, to visualize bone contour, which aids in the selection of the implant size and type, and also to optimize the implant location and angulation.<sup>[4]</sup>

Alveolar bone has a thin cortical plate and is difficult to identify the boundaries of the bone in radiographic images.<sup>[5]</sup> Much of the alveolar bone surface is also penetrated by gingival fibers, which may further mask the boundary between hard and soft tissues.<sup>[6]</sup> In addition to the properties of the alveolar bone itself, several other factors can also potentially affect the accuracy of measuring alveolar bone from CBCT images.<sup>[7]</sup> One such factor is voxel size of the CBCT which affects the accuracy of linear measurements of alveolar bone from CBCT images.<sup>[6,8]</sup>

CBCT offers isotropic voxels of various sizes. It is known that the smaller the voxel size, the greater the spatial resolution, rendering a better precision for measurement. On the contrary, smaller the voxel size, greater is the amount of radiation. Voxel resolution helps in detecting the smallest difference in measurement which significantly provides optimum information regarding the linear distances.<sup>[9]</sup>

Literature offers few studies related to the image acquisition protocol for measuring small linear distance of thin structures

such as buccal and lingual bone plate.<sup>[10]</sup> The purpose of our study was to assess the effect of different voxel sizes on the accuracy of linear measurements of alveolar bone from CBCT by comparing them with physical measurement. Such assessments may be helpful in understanding CBCT imaging in diagnosis, treatment plan, and prognosis.

## Materials and Methods

The objective of the study was to evaluate and compare the buccal and lingual bone plate thickness and to evaluate the alveolar bone crest level measurements on CBCT images with 0.2 mm and 0.4 mm voxels and to compare it with direct measurements. The ethical clearance to conduct the study was obtained from the Institutional Ethical Committee of KLE Society's Institute of Dental Sciences, Bengaluru. Thirty dry human mandibles were obtained for the study from the Department of Human Anatomy and Histology, KLE Society's Institute of Dental Sciences. Unbroken, partially dentulous with three consecutive posterior teeth, and edentulous human mandibles with sockets were included in this study. Damaged, mutilated, and deformed mandibles were excluded from the study.

## Methodology

Each dry human mandible was visually examined by direct inspection. Fifteen partially dentulous mandibles with three posterior consecutive teeth were taken for the measurements of alveolar crestal bone height. Fifteen edentulous sites with posterior sockets were taken for measuring buccal and lingual bone plate thickness. Each mandible was subjected for CBCT (Planmeca with the image acquisition protocol of 0.2 mm and again with 0.4 mm voxel sizes). Axial sections were used to measure the buccal and lingual bone thickness and were measured 12 mm above the mental foramen [Figure 1]. Using Planmeca Romexis software, the coronal sections were used to measure the buccal and lingual alveolar crestal bone height, which were measured from the cemento enamel junction (CEJ) to the crest of the alveolar bone [Figure 2].

Digital Vernier caliper was used for direct measurement. Buccal and lingual alveolar crestal bone height was measured from the CEJ to the crest of the alveolar bone. Buccal bone thickness was measured from 12 mm above the mental foramen [Figure 3]. The corresponding position of the mental foramen on the lingual side was measured for the lingual bone plate thickness.

Direct measurement using digital Vernier caliper was taken as the gold standard. Further, the comparison was done between 0.2 mm and direct measurement, 0.4 mm and direct measurement, and 0.2 mm and 0.4 mm. Further, the data were subjected to statistical analysis. The mean value was compared using paired *t*-test. The level of statistical significance was set as  $P \leq 0.05$ . The mean value obtained from 15 partially dentulous mandibles with three posterior consecutive teeth was taken for the measurements of alveolar crestal bone height. Fifteen

edentulous sites with posterior sockets were taken for measuring buccal and lingual bone plate thickness using dry mandible.

## Results

The mean buccal cortical plate thickness in 0.2 mm voxel, 0.4 mm voxel, and direct measurement is  $4.18 \pm 3.07$ ,  $5.18 \pm 3.10$ , and  $4.17 \pm 3.08$ , respectively. Mean lingual cortical plate thickness in 0.2 mm voxel, 0.4 mm voxel, and direct measurement is  $2.87 \pm 1.28$ ,  $3.55 \pm 1.00$ , and  $2.86 \pm 1.28$ , respectively. On comparison of buccal and lingual cortical plate thickness with direct measurement, no statistically significant difference was observed

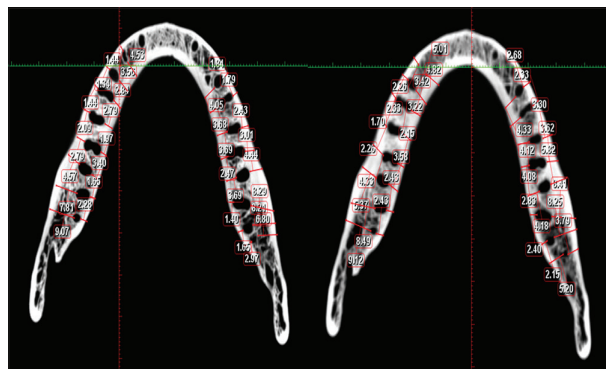


Figure 1: Measurements of alveolar buccal and lingual thickness with 0.2 mm and 0.4 mm voxel

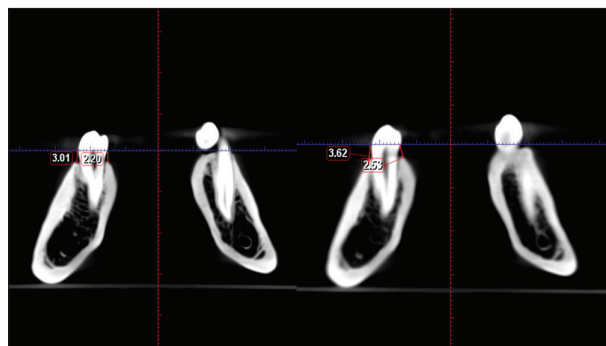


Figure 2: Measurement of buccal and lingual alveolar crestal height using 0.2 mm and 0.4 mm voxel

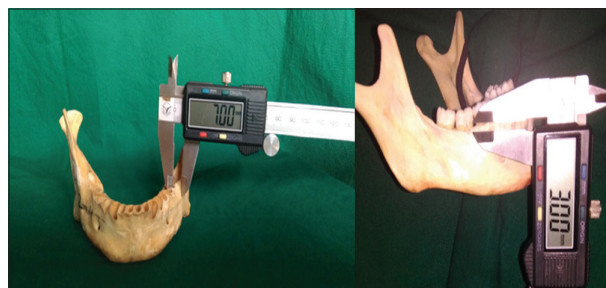

Figure 3: Measurements of buccal and lingual cortical plate thickness and alveolar crestal height with Vernier caliper

( $P > 0.05$ ). On comparison of buccal and lingual cortical plate thickness between 0.2 mm and 0.4 mm voxel, a statistically significant difference was observed ( $P < 0.05$ ) [Tables 1 and 2].

The mean buccal alveolar crestal height in 0.2 mm voxel, 0.4 mm voxel, and direct measurement is  $2.41 \pm 1.24$ ,  $2.80 \pm 1.36$ , and  $2.41 \pm 1.24$ , respectively. The mean lingual crestal height in 0.2 mm voxel, 0.4 mm voxel, and direct measurement is  $2.48 \pm 0.99$ ,  $2.92 \pm 1.02$ , and  $2.47 \pm 0.99$ , respectively. On comparison of the mean buccal and lingual alveolar crestal height with direct measurement, there was no statistically significant difference observed ( $P > 0.05$ ). On comparison of the mean buccal and lingual alveolar crestal height between 0.2 mm voxel and 0.4 mm voxel, statistically significant difference was observed with  $P < 0.05$  [Tables 3 and 4].

**Discussion**

CBCT imaging is a true shift from 2D imaging. CBCT is a popular imaging modality of high diagnostic value for evaluation, diagnosis, and treatment planning of orofacial structures.<sup>[1]</sup> CBCT evaluates small structures, in particular, alveolar bone thickness, and crestal bone height before and after treatment in orthodontic, periodontal, and implant placement. Enhanced image quality helps in assessment of small structures. The image quality depends on several factors such bit depth, exposure time, and spatial resolution. Spatial resolution counts on voxel dimension, which is the smallest image unit. A smaller voxel dimension leads to a greater image resolution, but necessitates a higher dose of radiation.<sup>[11]</sup>

**Table 1:** Mean buccal and lingual cortical plate thickness in mm between 0.2 mm voxel, 0.4 mm voxel, and direct measurement using paired sample *t*-test

Region	Method (mm)	n	Mean±Std. dev.	Mean diff.	t	P-value
Buccal	CBCT 0.2	44	4.18±3.07	0.01	0.59	0.55
	Direct	44	4.17±3.08			
Lingual	CBCT 0.2	44	2.87±1.28	0.00	1.83	0.07
	Direct	44	2.86±1.28			
Buccal	CBCT 0.4	44	5.18±3.10	1.01	12.79	0.001
	Direct	44	4.17±3.08			
Lingual	CBCT 0.4	44	3.55±1.00	0.69	7.80	0.001
	Direct	44	2.86±1.28			

**Table 2:** Mean buccal and lingual cortical plate thickness in mm between 0.2 mm voxel and 0.4 mm voxel measurements using paired sample *t*-test

Region	Method (mm)	n	Mean±Std. dev.	Mean diff.	t	P-value
Buccal	CBCT 0.2	44	4.18±3.07	-1.00	-12.31	0.001
	CBCT 0.4	44	5.18±3.10			
Lingual	CBCT 0.2	44	2.87±1.28	-0.68	-7.75	0.001
	CBCT 0.4	44	3.55±1.00			

The increasing applicability of CBCT in dentistry calls to determine which image acquisition protocol is capable of providing an appropriate resolution to measure small structures such as buccal and lingual cortical plates and linear structures such as alveolar crestal height. There are few studies which evaluate precision, reproducibility, and accuracy of tomographic measurements related to image acquisition protocol. Thus, this study was intended to measure the accuracy of alveolar bone plate thickness and alveolar bone crestal level using different voxel sizes (0.2 mm and 0.4 mm) and was compared with direct physical measurements.

In this study, the buccal and lingual cortical plate thickness and crestal bone height measurements obtained with 0.2 mm voxel were compared with direct measurements, which revealed no statistically significant difference. The image obtained in 0.2 mm voxel is capable of providing appropriate resolution and sharpness for measuring small structures such as buccal and lingual bone plates. These results were in accordance with the previous studies conducted by Sun *et al.*<sup>[11]</sup> In contrary, the study conducted by Ganguly *et al.* stated that there was statistical significance between alveolar crestal bone height and direct measurements, this was because X-ray beam undergoes attenuation on passing through bone, the image contrast is more when bone is imaged against air in dry mandible which delineates structures and boundaries.<sup>[12]</sup> However, in our study, there was no inconsistency in measurements obtained in 0.2 mm voxel size, and also, there was no statistical significance when compared with direct measurements.

**Table 3:** Mean buccal and lingual crestal bone height in mm between 0.2 mm voxel, 0.4 mm voxel, and direct measurements using paired sample *t*-test

Region	Method (mm)	n	Mean±Std. devt.	Mean diff.	t	P-value
Buccal	CBCT 0.2	35	2.41±1.24	0.00	3.10	0.07
	Direct	35	2.41±1.24			
Lingual	CBCT 0.2	35	2.48±0.99	0.00	3.59	0.06
	Direct	35	2.47±0.99			
Buccal	CBCT 0.4	35	2.80±1.36	0.41	7.80	0.001
	Direct	35	2.41±1.24			
Lingual	CBCT 0.4	35	2.92±1.02	0.46	9.79	0.001
	Direct	35	2.47±0.99			

**Table 4:** Mean buccal and lingual crestal bone height in mm between 0.2 mm and 0.4 mm voxel sizes using paired sample *t*-test

Region	Method (mm)	n	Mean±Std. devt.	Mean diff.	t	P-value
Buccal	CBCT 0.2	35	2.41±1.24	-0.38	-6.65	0.001
	CBCT 0.4	35	2.80±1.36			
Lingual	CBCT 0.2	35	2.48±0.99	-0.43	-9.40	0.001
	CBCT 0.4	35	2.92±1.02			

In this study, the buccal and lingual cortical plate thickness and crestal bone height obtained with 0.4 mm voxel were compared with direct measurements, which revealed a statistically significant difference. When a larger voxel of 0.4 mm is used, the interline distance required to separate four lines visually is 0.86 which is larger than the 0.4 voxel. Human vision is also influenced by lighting, fatigue, gray scale, and visual acuity. CBCT image contains 12/16 bits per pixel which corresponds to 4096–65,536 shades of gray, but human vision can only discriminate 700–900 shades of gray. Hence, when images are measured with 0.4 mm voxel, it overestimates the measurements.<sup>[13]</sup>

In our study, a statistically significant difference was observed on comparison of the buccal and lingual cortical plate thickness with 0.2 mm and 0.4 mm voxels. The results were in concordance with the studies done by Misch *et al.* and Timock *et al.* The authors stated that a smaller voxel size offers greater spatial resolution and sharpness which helps in identification of small structures, but a larger dose of radiation is offered for obtaining sufficient sharpness.<sup>[14,15]</sup> The studies done by Damstra *et al.* and de-Azevedo-Vaz *et al.* stated that if the thickness of alveolar bone is below the voxel size, then it would overestimate the thickness. If the bone becomes invisible while measuring on CBCT, it may be due to partial volume averaging effect and also due to contrast resolution related to CBCT machines. Another reason is when two objects of different densities lie within the voxel, it becomes indistinguishable from the adjacent structures.<sup>[16,17]</sup>

In our study, we measured the alveolar crest height using 0.2 mm and 0.4 mm voxel and there was statistically significant. CBCT provides images, which helps to evaluate alveolar bone height measurements with appropriate resolution and sharpness, which is good with smaller voxel size. Few studies conducted by de-Azevedo-Vaz *et al.* and Wood *et al.* stated that as alveolar crest is in close proximity with cementum, which has similar brightness and darkness of that of bone. Hence, it is difficult to measure and differentiate between these structures.<sup>[6,17]</sup>

The result of our present study demonstrated good precision and accuracy for measuring alveolar bone thickness and bone crestal level of mandibular posterior teeth on tomographic images using 0.2 mm voxel. Thus, this study recommends an image acquisition protocol with 0.2 mm voxel size when precise measurements are required for small structures, such as alveolar bone thickness and alveolar crestal bone height.

Limitations of the present study were as follows: Only dry mandibles were used and soft-tissue interface was not simulated. The study was accomplished with smaller sample sizes and anterior segment was not considered. Further, the study evaluated image protocols with 0.2 mm and 0.4 mm voxel sizes only, smaller voxel sizes <0.2 mm were not evaluated and also image protocols with 0.2 mm and 0.4 mm voxel sizes in different CBCT machines were not compared.

A specific diagnosis and treatment planning are the fundamentals for good prognosis. CBCT offers highly precise linear measurements of delicate structures, such as labial, buccal, and lingual bone. The accuracy of measurements with respect to linear distance is important for implant surgery orthodontic

treatment and periodontal problems. Precise measurements depend on the voxel dimension. A smaller voxel dimension leads to the greater image resolution but greater the amount of radiation.

The current study showed that the measurements of alveolar crest level and cortical plate thickness had a good accuracy and precision when measured with 0.2 mm voxel, than 0.4 mm voxel. Hence, for imaging smaller structures such as alveolar crest and buccal and lingual cortical plate thickness, the image acquisition protocol with 0.2 mm can be used for measuring such structures.

## Conclusion

The current study showed that the measurements of alveolar crest level and cortical plate thickness had a good accuracy and precision when measured with 0.2 mm voxel, than 0.4 mm voxel. Hence, for imaging smaller structures such as alveolar crest and buccal and lingual cortical plate thickness, the image acquisition protocol with 0.2 mm can be used for measuring such structures.

## References

1. Padmanabhan S, Dommy A, Guru SR, Joseph A. Comparative evaluation of cone-beam computed tomography versus direct surgical measurements in the diagnosis of mandibular molar furcation involvement. *Contemp Clin Dent* 2017;8:439-45.
2. Ghali SR, Katti G. Cone beam computed tomography: A boon for maxillofacial imaging. *J Indian Acad Oral Med Radiol* 2017;29:30-4.
3. Venkatesh E, Elluru SV. Cone beam computed tomography: Basics and applications in dentistry. *J Istanbul Univ Fac Dent* 2017;51:S102-21.
4. Marins Bde R, Pramiu SE, Busato MC, Marchi LC, Togashi AY. Peri-implant evaluation of osseointegrated implants subjected to orthodontic forces: Results after three years of functional loading. *Dental Press J Orthod* 2016;21:73-80.
5. Prakash N, Karjodkar FR, Sansare K, Sonawane HV, Bansal N, Arwade R. Visibility of lamina dura and periodontal space on periapical radiographs and its comparison with cone beam computed tomography. *Contemp Clin Dent* 2015;6:21-5.
6. Wood R, Sun Z, Chaudhry J, Tee BC, Kim DG, Leblebicioglu B, *et al.* Factors affecting the accuracy of buccal alveolar bone height measurements from cone-beam computed tomography images. *Am J Orthod Dentofacial Orthop* 2013;143:353-63.
7. Hekmatian E, Jafari-Pozve N, Khorrani L. The effect of voxel size on the measurement of mandibular thickness in cone-beam computed tomography. *Dent Res J (Isfahan)* 2014;11:544-8.
8. Fang D, Jiang H, Lin Z. Evaluation of the accuracy of alveolar bone height measurement *in vitro* by cone beam computed tomography. *Hua Xi Kou Qiang Yi Xue Za Zhi* 2012;30:603-6.
9. Spin-Neto R, Gotfredsen E, Wenzel A. Impact of voxel size variation on CBCT-based diagnostic outcome in dentistry: A systematic review. *J Digit Imaging* 2013;26:813-20.
10. Menezes CC, Janson G, da Silveira Massaro C, Cambiaghi L, Garib DG. Precision, reproducibility, and accuracy of bone crest level measurements of CBCT cross sections using different resolutions. *Angle Orthod* 2016;86:535-42.



11. Sun Z, Smith T, Kortam S, Kim DG, Tee BC, Fields H. Effect of bone thickness on alveolar bone-height measurements from cone-beam computed tomography images. *Am J Orthod Dentofacial Orthop* 2011;139:e117-27.
12. Ganguly R, Ruprecht A, Vincent S, Hellstein J, Timmons S, Qian F. Accuracy of linear measurement in the Galileos cone beam computed tomography under simulated clinical conditions. *Dentomaxillofac Radiol* 2011;40:299-305.
13. White SC, Michael J. Oral radiology. Principles and interpretation. In: *Cone Beam Computed Tomography: Volume Acquisition*. 7<sup>th</sup> ed., Ch. 11. St. Louis: Mosby Elsevier; 2008. p. 185-6.
14. Misch KA, Yi ES, Sarment DP. Accuracy of cone beam computed tomography for periodontal defect measurements. *J Periodontol* 2006;77:1261-6.
15. Timock AM, Cook V, McDonald T, Leo MC, Crowe J, Benninger BL, *et al.* Accuracy and reliability of buccal bone height and thickness measurements from cone-beam computed tomography imaging. *Am J Orthod Dentofacial Orthop* 2011;140:734-44.
16. Damstra J, Fourie Z, Huddleston Slater JJ, Ren Y. Accuracy of linear measurements from cone-beam computed tomography-derived surface models of different voxel sizes. *Am J Orthod Dentofacial Orthop* 2010;137:16.e1-6.
17. de-Azevedo-Vaz SL, Vasconcelos Kde F, Neves FS, Melo SL, Campos PS, Haiter-Neto F. Detection of periimplant fenestration and dehiscence with the use of two scan modes and the smallest voxel sizes of a cone-beam computed tomography device. *Oral Surg Oral Med Oral Pathol Oral Radiol* 2013;115:121-7.

**How to cite this article:** Fasalkar SS, Shubha G, Praveen BN, Shubhasini AR, Keerthi G, Mukhia N. Determining the accuracy of measurement of alveolar bone crest level and bone plate thickness with cone-beam computed tomography using different voxel size. *J Med Radiol Pathol Surg* 2019;6(3):8-12