

CASE REPORT



Restoring emotional and psychological vision of a child with custom-made ocular prosthesis- A case report

Jogeswar Barman, Barasha Goswami, Nirupam Paul

Department of Prosthodontics, Regional Dental College, Guwahati, Assam, India

Keywords:

Custom made, enucleation, ocular prosthesis

Correspondence:

Dr. Barasha Goswami, Regional Dental College, Guwahati, Assam, India.

E-mail: barasha.goswami17@gmail.com

Received: 22 August 2018

Accepted: 21 September 2018

doi: 10.15713/ins.jmrps.144

Abstract

Loss of eye at an early stage of life not only affects the facial esthetics but also imparts a pervasive impact on the psychological health of the patient and often leads to social disability. A custom-made ocular prosthesis is an easy and promising mean of the rehabilitation of such defect helps in leading the patient into a normal social life. Hence, the present article describes a simplified technique of the fabrication of ocular prosthesis to rehabilitate an enucleation defect in 3½-year-old girl followed by surgical removal of retinoblastoma.

Introduction

Loss of eye due to congenital disorders, malignancy, and trauma, and viral and bacterial infections produces gross disfigurement of facial esthetics. This produces pervasive impact on the psychological health of the patient and often leads to social disability.

Retinoblastoma is the most common primary intraocular malignancy occurring in children affecting mostly between 0 and 4 years of age.^[1] This is one of the severe ocular diseases in children requiring surgical intervention such as enucleation, evisceration, or exenteration depending on the extent of severity. Enucleation is the most common surgical intervention where the entire eyeball is removed after severing the muscles and the optic nerve; in evisceration, the contents of the globe are removed leaving the sclera intact, and exenteration involves the removal of the entire contents of the orbit including the eyelids and the surrounding tissues.^[2] If conformer is not given at the time of surgery, fabrication of a definitive ocular prosthesis should begin as soon as the socket has healed. Ocular prosthesis in the form of the custom-made or prefabricated prosthesis is the excellent means of rehabilitation of patients who have undergone enucleation and evisceration of eye. The custom-made ocular prosthesis has more advantages being closely adapted to the underlying soft tissues avoiding collection of mucous in prosthesis-tissue interface.^[3]

The presented case in this article is the rehabilitation of ocular defect in a 3½-year-old girl with the custom-made ocular prosthesis following enucleation due to retinoblastoma.

Case Report

A 3½-year-old girl child referred to the Department of Prosthodontics, Regional Dental College and Hospital, Guwahati, India, from Guwahati Medical College and Hospital for prosthetic rehabilitation of ocular defect of the right eye [Figure 1]. A history from her parents revealed that she was diagnosed with retinoblastoma for which enucleation of the right eye was done in the same hospital. No ocular conformer or immediate prosthesis was given to the patient.

On examination, it was found that healing of the socket was complete with no inflammation or residual scar formation. Palpebral fissure was examined in open and closed position and found to be normal. Mobility of the posterior wall of the defect eye was normal during movements of the normal eye. There was no abnormality of tissue, adhesion found. There was adequate depth of the upper and lower fornices for the retention of the prosthesis.

Considering all factors, we decided to fabricate a custom ocular prosthesis for the patient. Consent was taken from her parents before proceeding to the fabrication procedure.

Procedure

An external tray impression technique was employed to make the impression of the defect. At first, an impression of the facial area corresponding to the defect eye was registered with the help

of putty elastomeric impression material (Heraeus Variotime Easy Putty by Kulzer). This impression was used as a template for the fabrication of custom external tray. A double thickness wax spacer was put over the template and tray was made up of pink autopolymerizing resin (RR Cold Cure Dental Products of India [DPI], India). Multiple perforations were done in the tray so that extra impression material can escape and mechanically locked within it. Tray extension was again checked in defect eye.

After the tray gets ready, 2% lignocaine topical gel is applied on the ocular tissue to reduce the irritability during impression and to make the patient comfortable. Socket was cleaned by irrigating with saline water and dried with cotton pallet. Eyelashes and eyebrow on the defect side were lubricated with white petroleum jelly to avoid sticking of the impression material.

Now, polyvinyl siloxane impression material (Heraeus Variotime Light Flow Light Body) is slowly injected into socket, and simultaneously, extra material is loaded in the custom external tray and placed over the previously injected impression material in the defect. The patient is directed to move the normal eye into various directions by moving a figure in front of the patient for her easy understanding. This causes functional movement of the defect eye and impression was recorded under functional state. Once set, impression was carefully removed and beading is done with the help of plaster pumice mixture (Kalabhai, India and DPI, India, respectively) followed by boxing with modeling wax (DPI, India) [Figure 2].

Impression was poured in two sections in type IV gypsum (Kalabhai Ultrarock Die stone, India). The first part was poured to fill the undercut created by the depth of the fornices. After the material completely set, three keyways were made by scrapping little amount of stone from the surface. Separating media (DPI, India) is applied on the surface and remaining part was completely poured.

The two-piece mold made from the ocular impression was separated, and the impression material and tray were removed. The mold was coated with a separating medium and melted modeling wax (DPI, India) is poured into the cavity through the opening. When the wax cooled, the mold was opened and the wax was removed. Sharp ridges and undesirable irregularities are eliminated carefully with the help of a wax carver and the surfaces of the wax pattern were made smooth. The wax pattern was tried in the socket and evaluation was done for proper fullness of the eyelids and contoured to simulate the contralateral normal eye. Modification and contouring were further done to improve the esthetic result. When the soft tissue contours in the wax pattern were judged to be satisfactory, pattern was finalized for the next step of iris positioning. Size of the iris and its positioning were done with the help of Adobe Photoshop matching the contralateral normal eye. Iris was obtained from the stock eye shell which closely resembled the color and size of the normal eye and positioned in the wax pattern by removing wax and pattern is tried in socket [Figure 3].

After that, pattern was invested in type III dental stone (Kalabhai, India) in two sections. The first part was poured till the height of contour of the wax pattern. Once the stone was

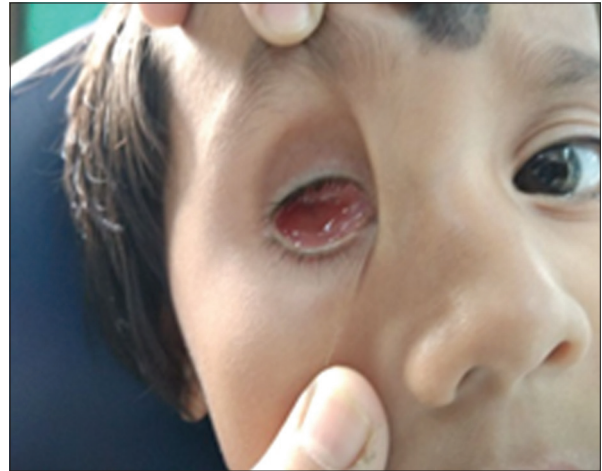

Figure 1: Preprosthetic view of enucleated eye




Figure 2: Impression of the eye, beading, and boxing

set, iris was carefully removed and remaining part was poured in Type III dental stone after applying separating medium.

After dewaxing, stone mold was packed with tooth-colored heat-cured acrylic resin (DPI, India) which simulates the color of the scleral blank of the normal eye. After curing, the prosthesis was removed carefully. Prosthesis was finished and polished and iris was repositioned in the prosthesis. It was tried in the patient's socket.

About 1 mm of acrylic was removed from the anterior surface of the prosthesis leaving the iris intact and again recontoured with wax (DPI, India) [Figure 4]. Prosthesis was reinvested like it was previously done and dewaxed. After dewaxing was completed, mold was opened and characterization of the prosthesis was executed.

Characterization was done with the help of camel oil-based watercolor and red-colored silk thread to simulate the minute detailing of the contralateral normal eye. Once characterization was judged to satisfactory, the mold with the prosthesis was packed with heat cure clear acrylic resin (Heat cure DPI, India)

which gave a natural shiny surface and lifelike appearance to the prosthesis. Before setting of the resin, mold is reopened and additional resin flowing over the iris was carefully removed with the help of a sharp scalpel. Mold was closed tightly and allowed to cure slowly over 1 h. Once curing is done, prosthesis was carefully removed [Figure 5]. After final finishing and polishing, prosthesis was fitted in the patients' socket. The patient was comfortable and happy. Easy steps of insertion and removal as well as instructions regarding cleanliness were given to the parents [Figure 6].

Discussion

Ocular prosthesis is an excellent means of restoring facial esthetics as well as improving quality of life. Losing eye at a very early stage often leads to social disability. In this situation, ocular prosthesis can give the patient a psychological strength; though it cannot restore the vision, it can restore the psychological eye. In the presented case, the patient was a young girl child who had to undergo enucleation of her right eye due to retinoblastoma. This age is too young to understand the grief of losing eye, but it is the awareness of her parents which can lead the patient into a normal life once she grows up. Hence, a custom ocular prosthesis using

poly methyl methacrylate (PMMA) was planned to enhance the confidence and quality of life of the patient.

Ocular prosthesis can be of various types: Stock eye shell, relining of stock eye shell, and custom-made ocular prosthesis.^[4-7] The custom-made ocular prosthesis has more advantages over stock prosthesis being accurate in fit and it provides good contour of sclera, improved adaptation to underlying tissues, thereby evenly distributing the pressure into the underlying tissue which eliminates tissue irritation.^[8] It also increases the mobility of the prosthesis, thereby making more lifelike. Accurate iris positioning is possible along with proper size of the pupil. Customization of color of the iris and sclera makes the prosthesis esthetically pleasing and having a lifelike appearance. Stock ocular prosthesis has poor tissue adaptation causes irritation in the eye and has poor esthetic outcome. Relineing of stock eye shell is done to improve fit, but esthetic is still compromised as customization of iris positioning and color as well as pupil size is not Possible 3. Considering all these factors, it was decided to fabricate a custom-made prosthesis for the patient.

In literature, black iris disc and painting on iris disc and paper iris disc with digital photography methods are mentioned to customize the Iris 2. However, this process requires considerable

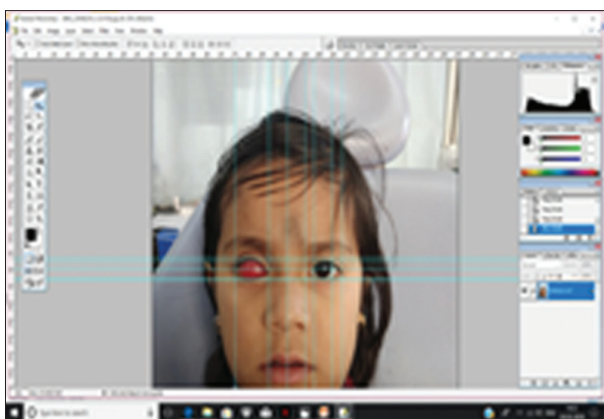

Figure 3: Wax pattern is tried in socket and iris positioning

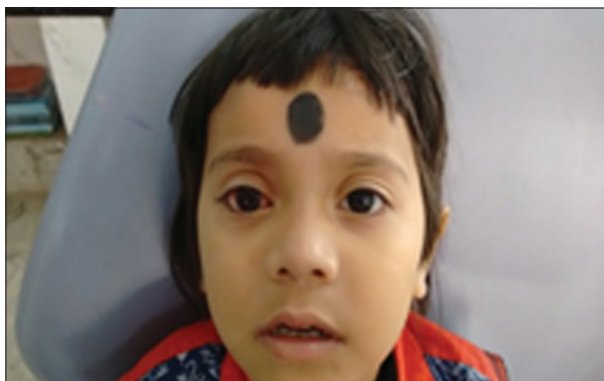

Figure 4: Recontouring of the prosthesis with wax before reinsertion and characterization



Figure 5: Characterized prosthesis

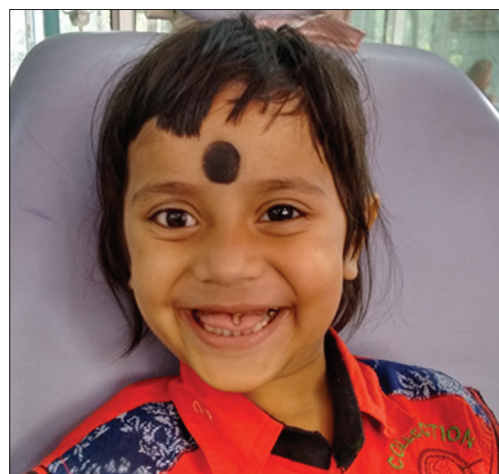

Figure 6: Final eye prosthesis

artistic skill and it is time consuming. Hence, in our case, we have used prefabricated iris shell matched with the patient's contralateral eye and artificial custom-made sclera was developed by heat cure tooth color acrylic resin making it inexpensive and less time consuming. The technique describes here for the fabrication of custom ocular prosthesis is easy with all easily available materials. Fabrication of base scleral cell was done first to facilitate characterization of the prosthesis followed by layering with clear acrylic resin which gave a lifelike appearance to the prosthesis after finishing and polishing. This double cure process reduces the free monomer which will ultimately decrease the tissue irritation and allergic reactions. Importance was given in finishing and polishing of the prosthesis which is very important to eliminate any tissue irritation under the prosthesis.

There are various impression techniques available for ocular prosthesis advocated by different authorities: The direct impression/external impression, impression with stock ocular tray, stock ocular tray modifications, impression with custom ocular tray, impression using stock ocular prosthesis, ocular prosthesis modification, and wax scleral blank technique. Each of them has their own advantages and ease of working. However, the ultimate goal is to get an accurate impression with accurately fitting extraoral prosthesis. In our case, we have used impression with custom external tray.

Various materials are being used for custom-made ocular prosthesis fabrication from the past. Glass was once the preferred prosthetic material, but due to difficulty in molding and its fragile nature, it is seldom used today. Modern ocular prosthesis is fabricated using either PMMA or ceramics. Ease of molding into any desired shape and its intrinsically inert nature make PMMA as the material of choice in fabricating ocular prosthesis in our case.

Ocular implants are another excellent means of rehabilitation of the ocular defect because it provides mobility and improved retention. Magnet retention and retention using tissue undercuts can also be used. Although osseointegrated implant may provide the most reliable prosthesis retention, additional surgeries, expenses, inadequate bone, and prior radiation to the area may contraindicate this type of treatment. In the present case, retention was primarily achieved through anatomic tissue undercut.

Conclusion

Rehabilitation of ocular defect in the form of custom ocular prosthesis is a promising approach for the patient. Implant-retained prosthesis shows improved retention, but due to its high cost, it is not practiced commonly. The custom-made prosthesis is more economic yes serving purpose of esthetics, comfort, and socialization. In the described case, rehabilitation of pediatric patient is challenging and it requires long-term follow-up till the development of the enucleated socket is complete at the age of 12 years. In this long observation period, childhood patient needs psychological support to recover confidence and self-esteem in today's cosmetically challenging world.

References

1. Dimaras H, Kimani K, Dimba EA, Gronsdahl P, White A, Chan HS, *et al.* Retinoblastoma. *Lancet* 2012;379:1436-6.
2. Taylor T. *Clinical Maxillofacial Prosthetics*. Illinois: 2000 Quintessence Publishing Co, Inc.; 2000. p. 233-76.
3. Cain JR. Custom ocular prosthetics. *J Prosthet Dent* 1982;48:690-4.
4. Rahn AO, Boucher LJ. Orbital and ocular prostheses. In: Rahn AO, Boucher LJ, editors. *Maxillofacial Prosthetics: Principles and Concepts*. Philadelphia, PA: Saunders; 1970. p. 164-7.
5. ChalianVA. Treating the patient with facial defects. In: Laney WB, editor. *Maxillofacial prosthetics*. Littleton, MA: PSG Publishing Co; 1979. p. 286.
6. Sykes LM. Custom made ocular prostheses: a clinical report. *J Prosthet Dent* 1996;75:1-3.
7. Welden RB, Niiranen JV. Ocular prosthesis. *J Prosthet Dent* 1956;6:272-8.
8. Cain JR. Custom ocular prosthetics. *J Prosthet Dent* 1982;48:690-4.

How to cite this article: Barman J, Goswami B, Paul N. Rehabilitation of ocular defect with custom-made ocular prosthesis - A case report. *J Med Radiol Pathol Surg* 2018;5:19-22.