



# Personal identification using frontal sinus and nasal septum patterns in forensic medicine: A retrospective digital radiographic study

Tejavathi Nagaraj, Haritma Nigam, H. N. Santosh, C. K. Sumana, Sita Gogula, Poonam Sahu

Department of Oral Medicine and Radiology, Sri Rajiv Gandhi College of Dental Sciences and Hospital, Bengaluru, Karnataka, India

## Keywords

Forensic, frontal sinus, nasal septum

## Correspondence

Dr. Haritma Nigam, Department of Oral Medicine and Radiology, Sri Rajiv Gandhi College of Dental Sciences and Hospital, Bengaluru, Karnataka, India, E-mail: dr.haritmanigam@gmail.com

Received: 18 July 2017

Accepted: 20 August 2017

doi: 10.15713/ins.jmrps.105

## Abstract

**Background:** Deviation in patterns of frontal sinus (FS) and nasal septum (NS) help in identifying the deceased or alive in forensic medicine.

**Aim:** The present study was performed for gender determination and personal identification by observing the various patterns of FS and NS in posteroanterior (PA) cephalogram.

**Materials and Methods:** A total of 280 individuals between the age interval of 20 and 50 years were selected. PA cephalogram of the selected individuals was taken on ortho pantomo graph machine with cephalography attachment and Orthophos DS; Sidexis XG digital radiography system.

**Results:** In FS, symmetrical pattern 219 (78%), and in NS, straight 92 (33%) and sigmoid 91 individuals (33%) were found to be dominant. Both FS and NS patterns were also assessed together for each individual. Pearson's correlation coefficient was done, and  $r$  value was 0.994 with  $P < 0.00001$  ( $P < 0.05$ ) showing it as highly significant.

**Conclusion:** Usage of FS and NS patterns acts as an indicator for personal identification in forensic medicine.

## Introduction

Forensic dentistry is well-defined as “application of dental knowledge in the investigation of crime and administration of justice.”<sup>[1]</sup> The word forensic comes from Latin, that means “to the forum.” In 1970, Keiser–Neilson defined forensic odontology or forensic dentistry as “that branch of forensic medicine which in the interest of justice, deals with the proper handling and examination of dental evidence and also with proper evaluation and presentation of the dental findings.”<sup>[2]</sup>

Documentation is the foundation of a person's personality. According to the Acharya and Taylor, “the characterized by which a person may be recognized.”<sup>[3]</sup>

Forensic maxillofacial radiology, a specialized area plays an important role in any mass disasters such as natural calamities, criminal case investigations, burnt cases, and aircraft crashes where body relics dishonored.<sup>[4]</sup> Human identification is a most embodied field which obliges the manhood in different ways.<sup>[5]</sup> Most frequently hired means of identification include fingerprints, dental comparisons, and biological methods such as DNA profiling but when soft tissue of human remains become

decayed, DNA is severely degraded, or there are any alterations in dental comparisons in such cases identification becomes difficult.<sup>[6]</sup> Thereby, forensic radiology plays an important role in personal identification as well as gender determination.<sup>[4]</sup> In human, skull various structures such as frontal sinus (FS), nasal septum (NS), vascular groove patterns, and sella turcica can be appreciated and indicators in the identification of a person because of their exceptionality in every individual.<sup>[7,8]</sup>

FS is a pneumatized cavity situated between the exterior and interior cortical surface of the frontal bone. It is exceptional in every individual including a monozygotic twin. Like FS, NS pattern is an advantageous and inimitable tool. Hence, conserving the antemortem, and then, comparing them with the post-mortem accounts will play a useful tool in the identification of a person or an individual.<sup>[9,10]</sup> Here, comes the role of radiologists and radiographs play a critical role and are universally acknowledged as a significant tool in personal in identification process as these are modest, cost-effective, and practical method.<sup>[4,11]</sup>

Hence, in the present study was commenced to observe the discrepancies in FS and NS patterns as observed on a posteroanterior cephalogram for identification.

## Materials and Methods

A retrospective study was done among the patients reporting to the outpatient department of our department of oral medicine and radiology. A total of 280 individuals consisting of 150 men and 130 women, with age interval from 20 to 60 years were chosen. Individuals without any developmental craniofacial malformations and systemic conditions affecting growth, no history of trauma or any surgical intervention done in the maxillofacial region, and without any clinical or radiographic pathology were included in the present study. Panoramic radiographs of the patients were taken using a panoramic component Orthophos DS; Sidexis XG for children 14.1 s, 62 kVp, and 8 mA and adults 14.1 s, 64 kVp, and 8 mA and were interpreted.

Obtained radiographs were subjected for the investigation of FS and NS patterns. FSs were evaluated for symmetry, as right or left dominant asymmetry, unilateral, or bilateral aplasia. The present study followed the criteria of Tanuguchi *et al.*, according to which symmetry was assessed by measuring greatest horizontal dimension from midline septum on the either side and difference in right and left side dimensions was divided by greatest dimension and multiplied by 100. If the percentage obtained was >20%, it was classified as asymmetrical, and NS was classified according to the direction of deviation of the septum as straight, deviation to right or left side, and sigmoid type. The data obtained were tabularized, and statistical analysis was done for the same using Pearson correlation coefficient test.

## Results

A total of 280 individuals were observed for FS and NS variation deviation patterns with 150 males and 130 females. In FS patterns, symmetrical patterns were found in 219 (78%) individuals with 114 seen in males and 105 in females. Asymmetrical patterns were found in 32 (11.2%) individuals with 10 right males and 8 right females and 8 left males and 6 left female. Unilateral aplasia were found in 16 (5.7%) individuals with 9 males and 7 females, and bilateral aplasia patterns were found in 13 (4.6%) individuals with 6 males and 7 females [Figure 1 and Table 1].

In NS deviations, straight was present in 92 (33%) individuals with 52 males and 40 females, right deviation was present in 58 (21%) individuals with 30 males and 28 females, left deviation was present in 39 (14%) individuals with 22 males and 17 females, and sigmoid deviation was present in 91 (33%) individuals [Figure 2 and Table 2].

On overall comparison, the symmetrical pattern was found to be dominant in FS found in 219 (78%) individuals, and in NS, dominancy was found in straight 92 (33%), sigmoid 91 individuals (33%) [Graphs 1 and 2].

Pearson correlation coefficient was calculated;  $r$  value was 0.994 with  $P < 0.00001$  ( $P < 0.05$ ) and the results were highly significant.

**Table 1:** Patterns of FS

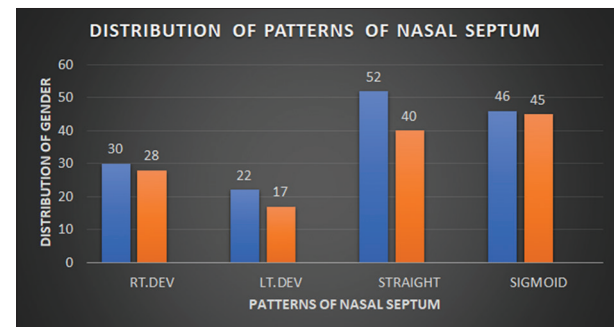
Patterns	Symmetry	Asymmetry	U/L aplasia	B/L aplasia
Total (280)	219	32	16	13
Percentage	78 (219/280)	11.4 (32/280)	5.7 (16/280)	4.6 (13/280)

FS: Frontal sinus

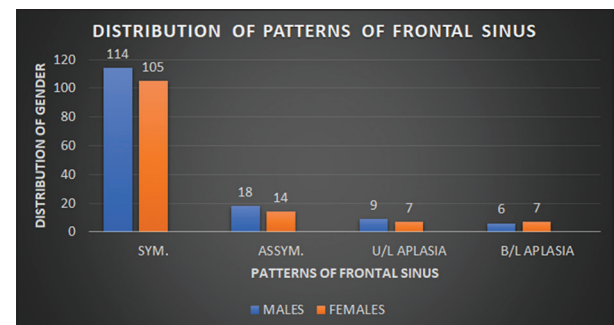
**Table 2:** Patterns of NS

Patterns	Straight	Right deviated	Left deviated	Sigmoid
Total (280)	92	58	39	91
Percentage	33 (92/280)	21 (58/280)	14 (39/280)	33 (91/280)

NS: Nasal septum



**Graph 1:** Gender distribution of frontal sinus

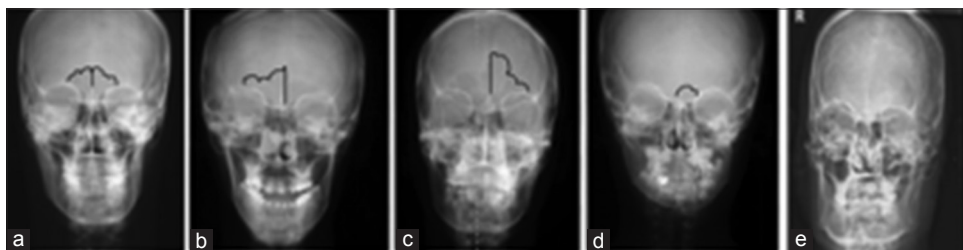


**Graph 2:** Gender distribution of nasal septum

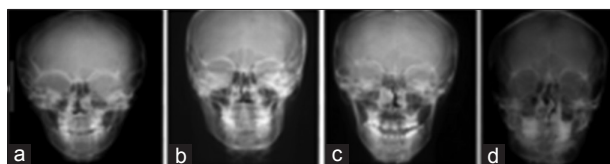
## Discussion

Radiographs are found to be one of the most consistent and fastest means of identification. Culbert and law did first human identification using morphological analysis for FS, in 1927. Zukerkandl *et al.* used FS patterns for identification as unique parameter due to its asymmetrical morphology, in 1875. According to Camarago *et al.*, the development of FS is completed in both genders by 20 years.<sup>[12-14]</sup>

Comparison of skeletal structures, by superimposing antemortem and post-mortem records, is very useful in identification.<sup>[9,10]</sup> For personal identity, radiographs of FSs are magnificently used in today's era of forensic medicine. The FSs are not evident at the time of birth, but they gradually develop at the age of 2 years gets completed at the age of 20 years.<sup>[7,8]</sup>



**Figure 1:** Patterns of frontal sinus: (a) Straight, (b) right dominant, (c) left dominant, (d) unilateral aplasia, (e) bilateral aplasia



**Figure 2:** Patterns of nasal septum: (a) Straight, (b) right deviated, (c) left deviated, (d) sigmoid

In various studies, it is detected that the development of the FS and NS usually completes by about 18-20 years of age. The FS is unique in itself showing functionally distinct configuration, individual differences.<sup>[15]</sup> Although NS also shows individual variations, but no population statistics are available.<sup>[15]</sup>

In the present study, FS symmetry and asymmetry were found to be in 78% and 11.4%, respectively, which were in total contrast with the studies done by Reddy *et al.* (2014) where it was found to be 29% and 71%, respectively, and Taniguchi *et al.* as 43.1% and 32%, respectively.<sup>[5,6]</sup> Bilateral aplasia was found to be 4.6% in our study which was in total contrast with the studies done by Gopal *et al.* (2017) who did not observe in any case and Taniguchi *et al.* in which 10.8% were found.<sup>[6,16]</sup> Unilateral aplasia was found in 5.7% which was in total contrast with Verma *et al.* as 8.7% and Gopal *et al.* (2016) as 2.5%.<sup>[16,17]</sup>

In the present study, the patterns of NS were observed as straight as 33%, right deviation as 21%, left deviation as 14%, and sigmoid as 33% which was in total contrast with the studies done by David and Saxena as 22%, 42%, 30%, and 2%, respectively, and by Taniguchi *et al.* as 13.4%, 37.6%, 35.3%, and 6.3%, respectively.<sup>[4,6]</sup>

The gender distribution was found to be male dominant in all the patterns of FS and NS except in case of bilateral aplasia in which female dominance was observed which was in total contrast with the study done by Verma *et al.* where although equal distribution of NS and FS was present except in right dominated asymmetrical FS and Reddy *et al.* where males and females were equally distributed.<sup>[5,17]</sup>

## Conclusion

In personal identification, the use of FS and NS has been sparingly explored. This study throws light on the fact that the varying patterns of FS and NS taken distinctly can be a useful aid in identifying individuals in the field of forensic medicine. To

strengthen the evidence that FS and NS deviation can be a stable landmark in personal identification, studies have to be done on larger and different populations on combining the aspect of FS and NS.

## References

1. Tekade P. Forensic dentistry: A review. *Int J Appl Biol Pharm Technol* 2011;2:265-272.
2. Rajendran R. Benign and malignant tumors of the oral cavity. In: Rajendran R, Sivapathasundharam B, editors. *Shafer's Textbook of Oral Pathology*. India: Elsevier, a Division of Reed Elsevier India Private Limited; 2006. p. 871-899.
3. Acharya AB, Taylor JA. Are a minimum number of concordant matches needed to establish identity in forensic odontology? *J Forensic Odontostomatol* 2003;21:6-13.
4. David MP, Saxena R. Use of frontal sinus and nasal septum patterns as an aid in personal identification: A digital radiographic pilot study. *J Forensic Dent Sci* 2010;2:77-80.
5. Reddy S. Unleash the unknown-frontal sinus and nasal septal patterns in personal identification. *Int J Dent Sci Res* 2014;2:141-145.
6. Taniguchi M, Sakoda S, Kano T, Zhu BL, Kamikodai Y, Fujita MQ, *et al.* Possible use of nasal septum and frontal sinus patterns to radiographic identification of unknown human remains. *Osaka City Med J* 2003;49:31-38.
7. Vidya CS, Shamsundar NM. Computerized tomographic study of frontal sinus [2] patterns in skulls of south Indian population. *Int J Sci Res Public* 2014;4:1-5.
8. Belaldavar C, Kotrashetti VS, Hallikerimath SR, Kale AD. Assessment of frontal sinus dimensions to determine sexual dimorphism among Indian adults. *J Forensic Dent Sci* 2014;6:25-30.
9. Pondé JM, Andrade RN, Via JM, Metzger P, Teles AC. Anatomical variations of the frontal sinus. *Int J Morphol* 2008;26:803-808.
10. Pobornikova S. An x-ray investigation of the development of the frontal sinuses in children. *Folia Med (Plovdiv)* 1974;16:213-220.
11. Kirk NJ, Wood RE, Goldstein M. Skeletal identification using the frontal sinus region: A retrospective study of 39 cases. *J Forensic Sci* 2002;47:318-323.
12. Zunkerandl E, Lichtwitz L, Garnault P. Normal and pathological anatomy of the nasal cavity. In: *Anatomy of the Frontal Sinus*. 3<sup>rd</sup> ed., Vol. 1. Paris: G Masson; 1895. p. 349-361.
13. Culbert WI, Law FM. Identification by comparison of roentgenograms of nasal accessory sinuses and mastoid processes. *J Am Med Assoc* 1927;88:1634-1636.
14. Camarago JR, Daruge E, Prado FB, Caria PH, Alves MC,

- Silva RF, *et al.* The frontal sinus morphology in radiographs of Brazilian subjects: Its forensic importance. *Braz J Morphol Sci* 2007;24:239-243.
15. Nambiar P, Naidu MD, Subramaniam K. Anatomical variability of the frontal sinuses and their application in forensic identification. *Clin Anat* 1999;12:16-19.
16. Gopal KS, Vijayan BP. Significance of frontal sinus and nasal septum patterns in personal identification in forensics: A retrospective CBCT study. *Int J Oral Health Med Res* 2016;2:57-62.
17. Verma P, Verma KG, Khosa R, Kumar S, Basavaraju S, Patwardhan N. Combined use of frontal sinus and nasal septum patterns as an aid in forensics: A digital radiographic study. *North Am J Med Sci* 2015;7:47-52.

**How to cite this article:** Nagaraj T, Nigam H, Santosh HN, Sumana CK, Gogula S, Sahu P. Personal identification using frontal sinus and nasal septum patterns in forensic medicine: A retrospective digital radiographic study. *J Med Radiol Pathol Surg* 2017;4:5-8.