



Laryngeal cancer imaging and its extension evaluation: Intelligent analysis of 100 cases diagnosed at Setif Hospital in Algeria

Babouche Farid¹, Draouet Sebti², Hamdi-Cherif Mokhtar³, Bouharati Imene^{1,4}

¹Department of Radiology, University Hospital of Setif, Setif, Algeria, ²Department of Radiology, Constantine University Hospital, Algeria, ³Laboratory of Health and Environment, Faculty of Medicine, UFAS, Setif1 University, Algeria, ⁴Laboratory of Intelligent Systems, UFAS, Setif1 University, Algeria

Keywords:

Artificial intelligence, clinical management, fuzzy logic, imaging, laryngeal cancers, scanner

Correspondence:

Dr. Babouche Farid, Department of Radiology, Faculty of Medicine, UFAS Setif1 University, Algeria.
E-mail: vicedoyenpedagogie@outlook.com

Received: 11 September 2018;

Accepted: 21 October 2018

Doi: 10.15713/ins.jmrps.141

Abstract

Background: Clinical examination and endoscopic biopsy are often not sufficient in the analysis of the evolution of laryngeal cancers. The imaging extension of laryngeal tumors is based on the helical multiband scanner.

Aims: Some deep extensions of the initial tumor pathology are only accessible using imaging. This is decisive in the therapeutic choice. It is the same in the case of ganglionic extensions in the management of lymphocytic tumors. The precise identification of these is necessary in the therapeutic orientation.

Materials and Methods: In our study, we give an overview of the imaging techniques used in the follow-up of 100 patients at the University Hospital of Setif in Algeria, and the impact of our imaging results on the prognosis and clinical management of these patients.

Results: From the results obtained in imaging of these patients, there are findings relating to volumes, shapes, density, location, and extension. These variations are very complex to analyze using conventional mathematical tools. We propose a system that uses artificial intelligence techniques for their analysis.

Conclusion: A fuzzy inference system is proposed. The input variables of the system express the tumor characteristics that are mapped to the output variable that expresses the therapeutic protocol to be adopted.

Introduction

Laryngeal cancers account for about 25% of all head cancers and malignant neck tumors. These cancers often occur in adults between the ages of 50 and 70 and affect men more than women.^[1] In the study area, the Setif region in Algeria, the national cancer registry reveals the male prevalence.

The dominant type of cancer in these cases is squamous cell carcinoma in about 90% of cases.^[2,3] People diagnosed with these types of cancers generally have a high risk of synchronous malignancies of the lung and the upper part of the aerodigestive tract.^[4]

Multiple risk factors ranging from environmental factors such as textile dust, polycyclic hydrocarbons and asbestos to squamous cell carcinoma of the larynx,^[5,6] alcohol, and tobacco are the most relevant with the highest rates.^[7-9] Diet also plays a non-negligible role in the appearance of these types of cancer.^[10,11] Studies are

needed to refine the effect of virus papillomas.^[12-16] Furthermore, it remains to demonstrate that laryngopharyngeal reflux has an effect on the appearance of these cancers.^[17,18]

Apart from endoscopy, cross-sectional imaging provides information on its submucosal extension, nodal diseases, and systemic metastases.^[19] The usefulness of radiography appears on the definition of the stage of the cancer of larynx, its anatomical aspect, and its propagation scheme and defines the planning of the treatment.^[19] The imaging modalities are multiple ranging from magnetic resonance imaging (MRI), computed tomography (CT), to positron emission tomography. Each technique has its own advantages and limitations. CT is most often used due to its high spatial resolution and availability as well as its permission to reveal soft tissue cancers. Comparing the standard MRI of the larynx to the CT scan, it takes a lot of time and requires the patient's involvement to improve the image. The image is influenced by the patient's breathing. An

intravenous contrast medium is useful in the assessment of lymph nodes.

In our diagnoses, the choice of imaging modality in cross-section of the larynx is performed with CT. The multicut scanner has allowed us to evaluate almost all relevant imaging issues. This technique is appropriate when it comes to exploring the nasosinus or otological symptoms caused by nasopharyngeal cancer. Since CT is the first-line imaging examination for signs of pharyngeal-laryngeal junction involvement, it has also allowed us to detect possible bone erosion of the skull base. In the case of clinically advanced forms, CT was sufficient to evaluate primary tumors and their ganglionic extensions. CT also presented a good prediction for tumors located on either side of a cartilage where asymmetric sclerosis of cricoid cartilage is observed. This finding is consistent with that of Cagli *et al.*^[20]

This study is devoted to the analysis of different tumor images of the 100 cases diagnosed in our radiology department. An intelligent analysis technique is proposed to refine information on tumor masses. The main information that characterizes these masses is the volume of the tumor, the shape of the mass that defines its anterior and posterior extensions, and its invasive degree of laryngeal cartilage.

What is observed is that these parameters are characterized by their uncertainty and imprecision. An analysis using a technique of artificial intelligence including the principles of fuzzy inference is proposed. As this technique deals with uncertainty, its application is adequate in our case. These parameters are considered as input variables to the system and the output result orients the arrangements to be made for each patient.

Materials and Methods

The starting data of the analysis of study variables are the recorded images. In our department of radiology, the images of 100 case studies presented to our service during a period of 6 years.

Each radiographic image is classified according to their approximate sizes by reference to standards classification, i.e., in four classes divided by an interval of 2 cm (<2, 2–4 cm, 4–6 cm, and >6 cm).^[21] This is because each tumor mass is distinguished by its volume. This is a critical factor in the prediction and treatment decision as well as the control after radiotherapy. Tumor masses are divided into supraglottic tumors whose volume is <6 ml and glottic tumors whose volume is <3.5 ml. These masses respond better to radiotherapy.^[22,23] This too has an impact on the surgical procedure to be adopted.^[24] In general, the classification of masses from T0 to T4 is based on sharp limits in terms of volume measurements.

However, it seems more reasonable to consider the uncertainty inherent in numerical measurement. Really, there is no significant difference between a mass of a diameter of 1.999 cm and 2.001 cm for example. Switching from one class to another seems to be imprecise, hence, the use of fuzzy inference that supports these uncertainties.

Shape

In radiology, it is necessary to know the potential routes to the larynx and pharynx. It must be taken into account that the tumor can extend to the piriform sinus from paraglottic fat and even extend under the cricoid cartilage to the upper esophagus of the subglottis. Such an extension will require additional pharyngeal resection. According to the geometrical shape of the tumor mass, the evaluation of the anterior factors and the posterior extensions is defined. In each class, three subsets are created according to the similarity of their irregular shapes. All the possibilities are met in the recorded forms in a random way. To decide on the extension, it becomes difficult to proceed by intuition. Fuzzy reasoning finds its perfect application.

Invasion of laryngeal cartilage

Although radiotherapy works well in tumors with limited cartilage involvement,^[25] invasion of this laryngeal cartilage is essential in imaging assessment. Depending on their size and shape, three classes that can invade the laryngeal cartilage are created. Defining the degree of such an invasion is difficult to assess accurately. Like human reasoning, the analysis used of the collected images gives better results in the prediction of these invasions.

Characteristics of the variables

The class-related parameters of the tumor masses are imprecise and uncertain. View these properties, they are considered as fuzzy variables. A fuzzy inference analysis is applied.^[26]

Fuzzy inference

Historically, the principles of fuzzy logic are presented for the 1st time in 1965 by Zadeh.^[27] This mode of reasoning is an imitation of human reasoning. As for the place of dealing with numerical variables, these are translated into linguistic variables. The operation of converting numeric variables into linguistics is called fuzzyfication. All the variables to be analyzed are fuzzyfied. The next step is to create a rule base from the actual values recorded. The rule base created must contain all possible combinations.

A rule is of the form:

$IF X_1 IS X_1(1) AND X_2 IS X_2(2) AND \dots X_n IS X_n(n) THEN Y_1 IS Y_1(1).$

This approach, taking into account all the complexity of the system, has made its application more generalized to different analyzes of data in the medical field.^[28]

Fuzzy modeling

The proposed fuzzy system has three input variables (volumes of tumor masses, their forms, and their ability to invade cartilage) and an output variable that expresses a classification according to the severity of this type of cancer [Figure 1].

[System]

Name='Larynx Cancer'

Type='mamdani'

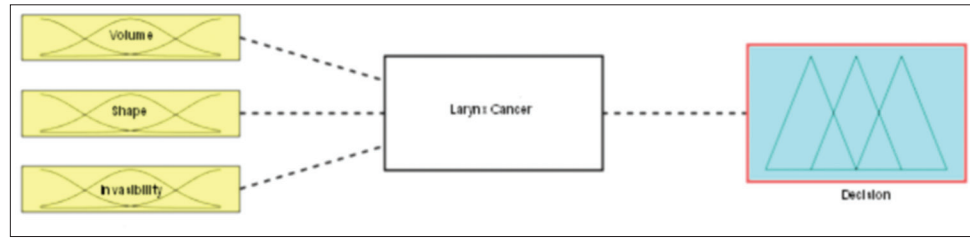


Figure 1: Block diagram of the system

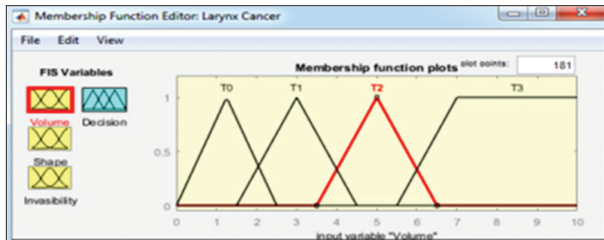


Figure 2: Fuzzyfication of the input variable “volume”

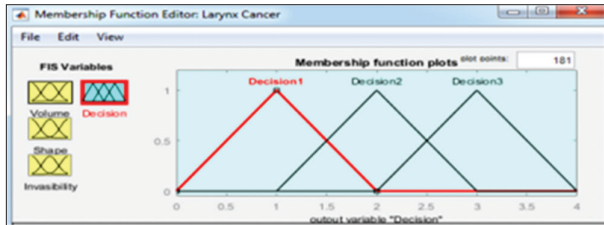


Figure 3: Fuzzyfication of the output variable “decision”

Version=2.0
 NumInputs=3
 NumOutputs=1
 NumRules=24
 AndMethod='min'
 OrMethod='max'
 ImpMethod='min'
 AggMethod='max'
 DefuzzMethod='centroid'

Fuzzyfication of variables

Input variables

The variable “volume”: This variable expresses the tumor volume recorded on radiology image. Depending on its diameter, each tumor mass is classified. Since the therapeutic orientation is defined from the volume, the numerical classification estimate below or above a sharp threshold cannot express the biological reality of the tumor effect. To overcome this inaccuracy, this variable is considered fuzzy and therefore fuzzyfied as follows [Figure 2]:

- T0: 0.0 <Diameter <2.5 cm
- T1: 1.5 <Diameter <4.5 cm
- T2: 3.5 <Diameter <6.5 cm
- T3: Diameter >5.5 cm.

```
[Input1]
Name='Volume'
Range=[0 10]
NumMFs=4
MF2='T0':'trimf',[0 1.25 2.5]
MF3='T1':'trimf',[1.5 3 4.5]
MF1='T2':'trimf',[3.5 5 6.5]
MF4='T3':'trimf',[5.5 7 1000000]
```

In the same way, the other input variables (shape and invasibility) are fuzzyfied in intervals that present fuzzy areas between each two neighboring membership functions.

```
[Input2]
Name='Shape'
Range=[0 4]
NumMFs=3
MF1='Shape1':'trimf',[0 1 2]
MF2='Shape2':'trimf',[1 2 3]
MF3='Shape3':'trimf',[2 3 4]

[Input3]
Name='Invasibility'
Range=[0 4]
NumMFs=3
MF1='Degree1':'trimf',[0 1 2]
MF2='Degree2':'trimf',[1 2 3]
MF3='Degree3':'trimf',[2 3 4]
```

Output variable

The output variable expresses the synthesis of the contribution of all fuzzyfied input values to classify the tumor mass according to its invasive degree and thus directs the therapeutic procedure. Here too, to compensate uncertainty, fuzzy areas are created between two neighboring membership functions. This quantification is expressed in numerical terms from 0 to 4 as follows [Figure 3]:

- First decision 0 <value <2
- Second decision 1 <value <3
- Third decision 2 <value <4

```
[Output1]
Name='Decision'
Range=[0 4]
NumMFs=3
MF1='Decision1':'trimf',[0 1 2]
MF2='Decision2':'trimf',[1 2 3]
MF3='Decision3':'trimf',[2 3 4]
```

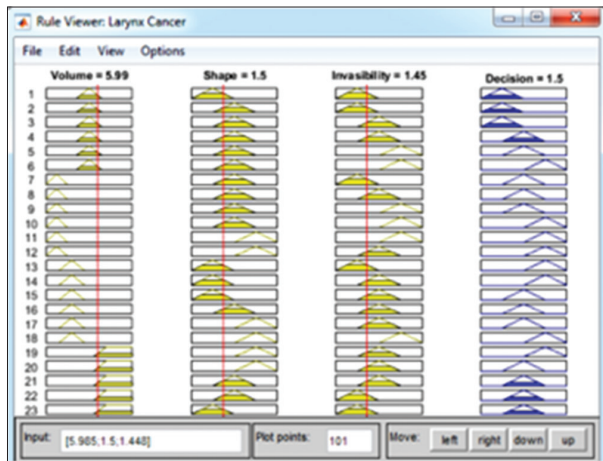


Figure 4: Application example

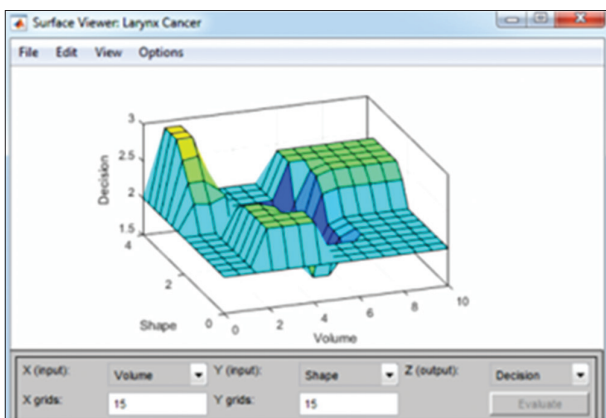


Figure 5: View surfaces

Inference rules

Each registered case is translated into an inference rule in the form:

IF “input 1” and “input 2” and “input 3” then “output.”

All possible combinations are introduced. The procedure of defuzzification leads to the result at the output.

Results and Discussion

The complexity of the system is offset by the fuzzyfication of the variables. All volumes of images are considered input variables as well as their shapes and possible cartilage invasions. The collaboration of all the input variables defines the output value from the previously established correspondence as a rule base. This result is the aggregation of the set of rules introduced from the real recorded images and the corresponding therapeutic procedures.

Once the system is established, this will automatically read the value at the output automatically from the input of the random values at the input [Figure 4]. It is also possible to vary these factors to visualize the effect of each on the output result.

Example:

- IF “volume” is 5.99 cm which corresponds to the T2 class.
- AND “form” is 1.5 which corresponds to the interval between the first class and the second class of the form (in this case, we consider two separate rules, in each rule, we assign the form to a class) that is where the advantage of the compensation of errors appears.
- AND “invisibility” is 1.45 which also corresponds to the interval between the first and the second degree.
- THEN “decision” is 1.5 which directs the suggested therapy between the first and the second decision.

The correspondence between the inputs and the output can also be represented by a surface curve [Figure 5].

Conclusion

CT imaging is of paramount importance and complements clinical endoscopy for laryngeal cancer. Therapeutic staging depends on it. This imaging is also necessary in the determination of the possible spread. Furthermore, this guide decisions regarding the treatment of patients with these cancers. To better interpret and have a better understanding of the characteristic patterns of these tumors, it is fundamental to analyze these images from the point of view of the main anatomical features. This is necessary in the classification and evaluation of systemic metastases.

In this spirit, this study deals with the N classification with the management of uncertainties and inaccuracies, particularly at the boundary between two neighbor classes. Furthermore, the same fuzzy reasoning is applied to the geometrical shape of the tumor mass and its possible extension. The mapping between the two input-output spaces, taking into account all the observations of the recorded images, makes it possible to obtain the most precise result possible with regard to the orientation of the corresponding therapeutic procedures.

The proposed system remains extensible to the variables that are not taken in this study and that may have an influence on the output result.

References

1. Baselga J. Why the epidermal growth factor receptor? The rationale for cancer therapy. *Oncologist* 2002;7 Suppl 4:2-8.
2. Parkin DM, Bray F, Ferlay J, Pisani P. Global cancer statistics, 2002. *CA Cancer J Clin* 2005;55:74-108.
3. Hashibe M, Boffetta P, Zaridze D, Shangina O, Szeszenia-Dabrowska N, Mates D, *et al.* Contribution of tobacco and alcohol to the high rates of squamous cell carcinoma of the supraglottis and glottis in central europe. *Am J Epidemiol* 2007;165:814-20.
4. Nikolaou AC, Markou CD, Petridis DG, Daniilidis IC. Second primary neoplasms in patients with laryngeal carcinoma. *Laryngoscope* 2000;110:58-64.
5. Stell PM, McGill T. Asbestos and laryngeal carcinoma. *Lancet* 1973;2:416-7.
6. Paget-Bailly S, Cyr D, Luce D. Occupational exposures and

- cancer of the larynx-systematic review and meta-analysis. *J Occup Environ Med* 2012;54:71-84.
7. Rothman KJ, Cann CI, Flanders D, Fried MP. Epidemiology of laryngeal cancer. *Epidemiol Rev* 1980;2:195-209.
 8. Kuper H, Boffetta P, Adami HO. Tobacco use and cancer causation: Association by tumour type. *J Intern Med* 2002;252:206-24.
 9. Boffetta P, Hashibe M. Alcohol and cancer. *Lancet Oncol* 2006;7:149-56.
 10. Di Maso M, Talamini R, Bosetti C, Montella M, Zucchetto A, Libra M, *et al.* Red meat and cancer risk in a network of case-control studies focusing on cooking practices. *Ann Oncol* 2013;24:3107-12.
 11. Garavello W, Lucenteforte E, Bosetti C, Talamini R, Levi F, Tavani A, *et al.* Diet diversity and the risk of laryngeal cancer: A case-control study from Italy and Switzerland. *Oral Oncol* 2009;45:85-9.
 12. Gama RR, Carvalho AL, Longatto Filho A, Scorsato AP, López RV, Rautava J, *et al.* Detection of human papillomavirus in laryngeal squamous cell carcinoma: Systematic review and meta-analysis. *Laryngoscope* 2016;126:885-93.
 13. Ndiaye C, Mena M, Alemany L, Arbyn M, Castellsagué X, Laporte L, *et al.* HPV DNA, E6/E7 mRNA, and p16INK4a detection in head and neck cancers: A systematic review and meta-analysis. *Lancet Oncol* 2014;15:1319-31.
 14. Chernock RD, Wang X, Gao G, Lewis JS Jr., Zhang Q, Thorstad WL, *et al.* Detection and significance of human papillomavirus, CDKN2A(p16) and CDKN1A(p21) expression in squamous cell carcinoma of the larynx. *Mod Pathol* 2013;26:223-31.
 15. Young RJ, Urban D, Angel C, Corry J, Lyons B, Vallance N, *et al.* Frequency and prognostic significance of p16(INK4A) protein overexpression and transcriptionally active human papillomavirus infection in laryngeal squamous cell carcinoma. *Br J Cancer* 2015;112:1098-104.
 16. Chung CH, Zhang Q, Kong CS, *et al.* p16 protein expression and human papillomavirus status as prognostic biomarkers of nonoropharyngeal head and neck squamous cell carcinoma. *J Clin Oncol* 2014;32:3930-3938.
 17. Zhang D, Zhou J, Chen B, Zhou L, Tao L. Gastroesophageal reflux and carcinoma of larynx or pharynx: A meta-analysis. *Acta Otolaryngol* 2014;134:982-9.
 18. Galli J, Cammarota G, Volante M, De Corso E, Almadori G, Paludetti G, *et al.* Laryngeal carcinoma and laryngo-pharyngeal reflux disease. *Acta Otorhinolaryngol Ital* 2006;26:260-3.
 19. Connor S. Laryngeal cancer: How does the radiologist help? *Cancer Imaging* 2007;7:93-103.
 20. Cagli S, Oztürk M, Yüce I, Deniz K, Güney E. The value of routine clinical and radiologic studies in predicting neoplastic invasion of cricoarytenoid units. *AJNR Am J Neuroradiol* 2009;30:1936-40.
 21. Park JY, Kim DY, Kim JH, Kim YM, Kim YT, Nam JH, *et al.* Outcomes after radical hysterectomy according to tumor size divided by 2-cm interval in patients with early cervical cancer. *Ann Oncol* 2011;22:59-67.
 22. Freeman DE, Mancuso AA, Parsons JT, Mendenhall WM, Million RR. Irradiation alone for supraglottic larynx carcinoma: Can CT findings predict treatment results? *Int J Radiat Oncol Biol Phys* 1990;19:485-90.
 23. Lee WR, Mancuso AA, Saleh EM, Mendenhall WM, Parsons JT, Million RR, *et al.* Can pretreatment computed tomography findings predict local control in T3 squamous cell carcinoma of the glottic larynx treated with radiotherapy alone? *Int J Radiat Oncol Biol Phys* 1993;25:683-7.
 24. Mukherji SK, O'Brien SM, Gerstle RJ, Weissler M, Shockley W, Castillo M, *et al.* Tumor volume: An independent predictor of outcome for laryngeal cancer. *J Comput Assist Tomogr* 1999;23:50-4.
 25. Thoeny HC, Delaere PR, Hermans R. Correlation of local outcome after partial laryngectomy with cartilage abnormalities on CT. *AJNR Am J Neuroradiol* 2005;26:674-8.
 26. Imane B, Khaoula B, Saddek B, Mokhtar HC. Functional magnetic resonance imaging: Fuzzy inference analysis. *Radiol Diagn Imaging* 2017;1:1-4.
 27. Zadeh LA. Fuzzy sets. *Inform Contr* 1965;8:338-53.
 28. Bouharati I, Babouche F, Bouharati K, Khenchouche A, Bouharati S. Brain tumor identification from MRI imaging using fuzzy inference. *Radiol Diagn Imaging* 2018;2:1-4.

How to cite this article: Babouche F, Draouet S, Hamdi-Cherif M, Bouharati I. Laryngeal cancer imaging and its extension evaluation: Intelligent analysis of 100 cases diagnosed at Setif Hospital in Algeria. *J Med Radiol Pathol Surg* 2018;5:6-10.